

# Nipple Temperatures in Breast Thermography

James Stewart Campbell<sup>1</sup>

<sup>1</sup> MEDesign LLC, Pfafftown, NC 27040, United States of America

## Abstract

**Objective:** Since the advent of microbolometer infrared imagers that allow qualitative and quantitative nipple temperature assessment, peer-reviewed guidelines have stated that normal differential nipple temperatures should not exceed 1.0 °C. This study is designed to examine the validity of this and other nipple temperature measurements in a clinical breast thermography population. **Methods:** 211 women between 27 and 83 years of age underwent standard breast thermography. Images of 422 breasts were taken and analyzed. Average area temperatures were obtained for both the breasts and nipples. Besides analyzing the combined data from all subjects, three subsets of data with different Thermobiological (TH) evaluations and a subset of women with bilateral breast implants were analyzed. **Results:** Absolute breast temperature declined about 1°C from age 27 to 83. Nipple temperature was unaffected by age. A strong correlation was found between ipsilateral breast and nipple temperatures. Nipple temperatures were cooler than the breast in 93.8% of 422 samples. Nipple temperature increased relative to the breast temperature as the TH evaluation increased. Average right breast and nipple temperatures were warmer than the Left in all data sets. Nipple temperature difference tends to rise faster than breast temperature difference. As the TH evaluation increased, differential breast temperatures remained constant while nipple differentials increased. Women with breast implants were found to have the least variation in breast and nipple temperatures. **Conclusions:** Normal nipple temperature is less than breast temperature by an average of 1.1°C. A cutoff value for maximum nipple temperature difference is graphically confirmed to be 1.0 °C. Maximum breast temperature difference cutoff is 0.5°C, and a vector sum of these differences should be less than 1.5°C. Nipple temperatures are controlled by sympathetic neural tone and by local nitric oxide concentration. Lactiferous duct infection and intraductal tumors (DCIS) increase intraductal NO, which is directed up the duct to the nipple. Increased nipple temperature may signal the presence of breast pathology.

**Keywords:** nipple; thermography; breast; DCIS; nitric oxide; sympathetic; autonomic.

## Resumo

**Objetivo:** Desde o advento dos microbolômetros infravermelhos que permitem a avaliação qualitativa e quantitativa da temperatura do mamilo, as diretrizes revisadas por pares afirmam que as temperaturas diferenciais normais do mamilo não devem exceder 1,0 °C. Este estudo é projetado para examinar a validade desta e de outras medições de temperatura do mamilo em uma população clínica de termografia de mama. **Métodos:** 211 mulheres entre 27 e 83 anos foram submetidas à termografia mamária padrão. Imagens de 422 seios foram tiradas e analisadas. As temperaturas médias da área foram obtidas para as mamas e mamilos. Além de analisar os dados combinados de todos os indivíduos, três subconjuntos de dados com diferentes avaliações termobiológicas (TH) e um subconjunto de mulheres com implantes mamários bilaterais foram analisados. **Resultados:** A temperatura absoluta da mama diminuiu cerca de 1°C dos 27 aos 83 anos. A temperatura do mamilo não foi afetada pela idade. Uma forte correlação foi encontrada entre as temperaturas ipsilaterais da mama e do mamilo. As temperaturas dos mamilos foram mais frias que as da mama em 93,8% das 422 amostras. A temperatura do mamilo aumentou em relação à temperatura da mama à medida que a avaliação de HT aumentou. As temperaturas médias da mama direita e do mamilo foram mais quentes que as da esquerda em todos os conjuntos de dados. A diferença de temperatura do mamilo tende a aumentar mais rapidamente do que a diferença de temperatura da mama. À medida que as avaliações termobiológicas (TH) aumentaram, as temperaturas diferenciais da mama permaneceram constantes enquanto as diferenciais do mamilo aumentaram. Verificou-se que as mulheres com implantes mamários têm a menor variação nas temperaturas dos seios e dos mamilos. **Conclusões:** A temperatura normal do mamilo é inferior à temperatura da mama em uma média de 1,1°C. Um valor de corte para a diferença máxima de temperatura do mamilo é confirmado graficamente como 1,0 °C. O limite máximo da diferença de temperatura da mama é de 0,5°C, e uma soma vetorial dessas diferenças deve ser inferior a 1,5°C. As temperaturas dos mamilos são controladas pelo tônus neural simpático e pela concentração local de óxido nítrico. Infecção do ducto lactífero e tumores intraductais (CDIS) aumentam o NO intraductal, que é direcionado pelo ducto até o mamilo. O aumento da temperatura do mamilo pode sinalizar a presença de patologia mamária.

**Palavras-chave:** mamilo; termografia; mama; CDIS; óxido nítrico; simpático; autonômico.

DOI: <http://dx.doi.org/10.18073/pajmt.2023.10.002>

## INTRODUCTION

With the introduction of microbolometer-based infrared imagers coupled to modern computers, the thermal and spatial resolution of medical infrared images has improved greatly. The older evaporograph or mechanical rotating-mirror infrared scanning technology before 2000 required several minutes to scan a subject (1). Patient movement, including respiration, along with mechanical inaccuracies in the scanning systems, degraded the spatial resolution significantly. Also, the limited greyscale or color values available in the older display and printing technologies severely limited the thermal resolution as seen by the human eye (2). Due to these limitations, the nipples were difficult to visually locate and measure quantitatively in female breast scans.

Elevated temperature has been associated with disease for centuries (3). Breast thermograms beginning the 1950's have visually confirmed this association as it relates to breast cancer (4). However, it was not until microbolometer-based infrared imagers began to be used medically around 2000 that nipple temperatures could be qualitatively located and measured.

Once they could be reliably assessed, nipple temperatures were found to be an important addition to breast thermography. The breast guidelines of the American Academy of Thermology (2021) state without reference that the magnitude of the Right-Left differential nipple temperature measurement should not exceed 1.0 °C (5).

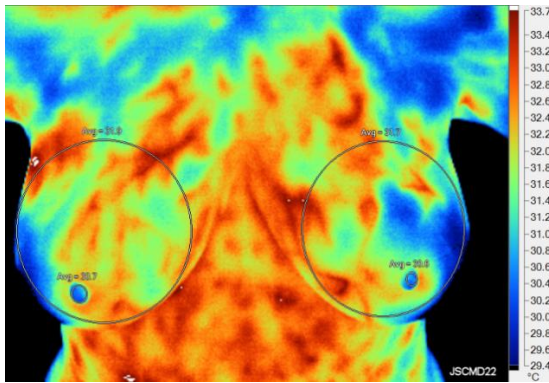
This study investigates the relationship of breast temperatures to nipple temperatures, differential nipple temperatures, and differential breast temperatures as obtained in a working thermography clinic. Thermobiologically Normal (TH1 & TH2), Thermobiologically Equivocal (TH3), and Thermobiologically Abnormal (TH4 & TH5) data sets were included in this study, as was a set that had bilateral breast implants.

## MATERIALS AND METHODS

In 2016 and 2017, 211 consecutive women between 27 and 83 years of age (average 58yrs) gave informed consent and underwent routine thermography of the breasts at a single-center thermography clinic in Clemmons, NC, USA. No woman was excluded from the test group. The women were given standard pre-thermography advice to prevent thermographic breast artifacts. Imaging took place after the subjects were temperature-equilibrated to 20-21°C in a thermally controlled interior room with no significant sources of infrared heat or airflow present. Subjects were unclothed above the waist during cool-down with arms held away from their sides. Examinations were interpreted by a single physician (JSC) using the standard Ville Marie "TH" Grading Scale which excluded nipple temperature as a grading factor at that time (6). Reports were then sent to both the patient and their provider.

### Thermal Image Acquisition

All thermograms were taken by a single infrared imager – a Fluke TiX-500 320x240-pixel uncooled microbolometer instrument with a coated germanium lens providing a 24 °H x 17 °V field of view in the 7.5 μm to 14 μm infrared band. Thermoelectric noise (NETD) is specified to be ≤ 0.05 °C at 30 °C for the TiX-500 (7). Imager offset at room temperature was measured and recorded immediately before each examination and, though variable from day to day, remained within the instrument's specification (+/- 2°C). Thermal gain of the imager was determined to be 1.0 across the physiologic range (20 to 40 °C), and 5-point image flatness was measured as 0.0°C (8). Surface emissivity was manually set at 0.98 to match that of human skin, and background temperature was set at 21°C. A hand-held imaging technique was used for the examinations to provide adequate bilateral frontal and close-up views of both breasts. Typical measurement sites are shown in Figure 1.



**Figure 1.** Average breast temperatures were determined by area measurement of at least the central 2/3 of the breast area. Nipple temperatures were average area measurements of the nipple only (not including the areola).

### Data Analysis

Thermal image scaling, quantitative measurement, annotation, interpretation, and reporting were performed with Fluke SmartView software version 4.3.122.0. Measurement report resolution was limited in software to 0.1°C. For each breast, two average area temperature measurements were made, one over the nipple (excluding the areola) and the other covering at least 2/3 of the central breast area. These measurement areas were visually chosen using a spectral full-span image formatting technique (8). All temperature measurements were corrected for the imager temperature offset before statistical analysis. The breast area measurement included the nipple area, but this overlap could be ignored because the nipple covered only 1 to 2% of the breast area and the maximum breast-nipple temperature difference was 4.7°C, creating an insignificant maximum breast temperature measurement error of 0.01°C. All measurements were entered into an Excel 2010 spread-sheet for statistical analysis and graphic display generation.

## RESULTS

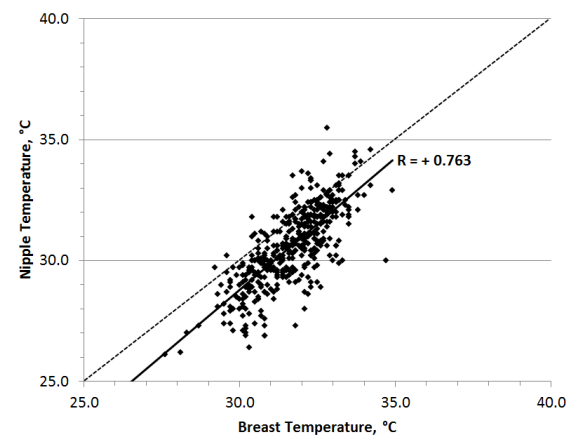
### Absolute Temperature Data

“Absolute” temperatures consist of the offset-corrected breast and nipple surface

temperatures measured in Centigrade degrees.

Using Pearson’s linear trendline analysis, absolute breast temperature declined about 1°C from age 20 to 80, but this decline was not significant ( $R = -0.167$ ). Absolute nipple temperature was virtually unaffected by age ( $R = -0.040$ ).

A strong linear Pearson’s correlation coefficient ( $R = +0.763$ ) was found on comparing all absolute breast versus nipple temperature pairs (the All Data set,  $N = 422$ ). For the vast majority of samples, the breast area was warmer than the nipple area (Figure 2).



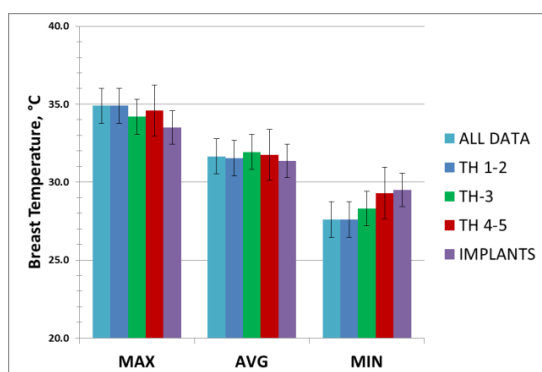
**Figure 2.** Scatter plot showing a strong correlation between breast and nipple temperatures. On average, breast temperature is 1.1 °C warmer than the nipple. Solid line is the linear trendline. Dotted line is the equal values line.

Along with the All Data set, four additional data sets were investigated using absolute temperatures. Because there were so few samples in the TH1 and TH5 interpretation categories, these were combined with the TH2 and TH4 categories, respectively, to make three TH sets (Table 1). Women with breast implants (all bilateral) were also examined as a set and were found to have the most uniform breast and nipple temperatures (the least Max minus Min), (Figures 3 and 4).

**Table 1.** Number of absolute temperature samples included in each data set.

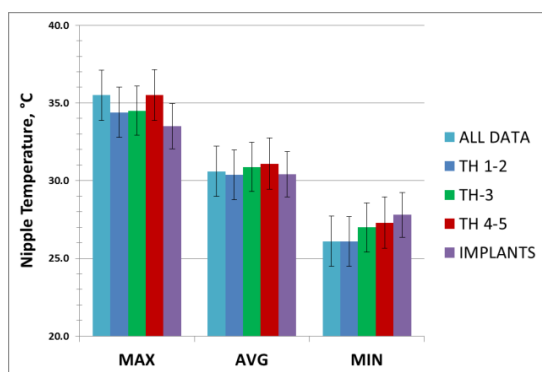
Set	Breast	Nipple
All Data	422	422
TH1&2 (Normal)	258	258
TH3 (Equivocal)	104	104
TH4&5 (Abnormal)	60	60
Implants	46	46

**Legend:** "TH" indicates the Thermobiological evaluation of the infrared breast image – TH1-2 = Normal, TH3 = Equivocal, and TH4-5 = Abnormal.



**Figure 3.** Maximum, average, and minimum absolute breast temperature measurements are shown for the five data sets. Error bars representing +/- 1 standard deviation are shown.

**Legend:** MAX = maximum temperature, AVG= average temperature, MIN = minimum temperature, "TH" indicates the Thermobiological evaluation of the infrared breast image – TH1-2 = Normal, TH3 = Equivocal, and TH4-5 = Abnormal.



**Figure 4.** Maximum, average, and minimum absolute nipple temperature measurements are shown for the five data sets. Error bars representing +/-1 standard deviation are shown.

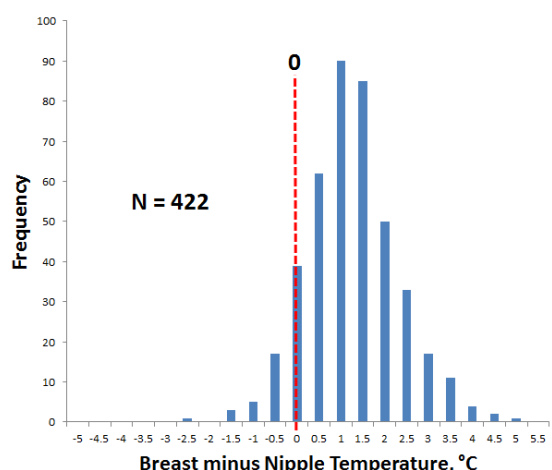
**Legend:** MAX = maximum temperature, AVG= average temperature, MIN = minimum temperature, "TH" indicates

the Thermobiological evaluation of the infrared breast image – TH1-2 = Normal, TH3 = Equivocal, and TH4-5 = Abnormal.

On observing the error bars for the data sets in Figures 3 and 4, it is apparent that these five different sets cannot be distinguished using absolute temperature values even in the aggregate. There are no significant trends to separate the data sets for either the breast temperatures or the nipple temperatures. This is due, in part, to the 1°C variation in the ambient temperature of the thermography room as well as other factors such as the ambient temperature, the subject's core temperature, and their brown fat thermogenesis, to name only a few confounding variables (9). To reduce these variations, differential temperature measurements were analyzed.

### Differential Temperature Data

Subtracting the nipple temperature from the ipsilateral breast temperature (Br-Nip) is useful to eliminate any variations in absolute temperature when evaluating the individual breast. As seen in Figure 5, a binned histogram of this calculation on the All Data set displays a Gaussian distribution that peaks at about +1°C. Statistical analysis gives an average Br-Nip value of +1.1°C and a Standard Deviation of 1.1°C for this data set.



**Figure 5.** Histogram of the All Data set showing that breast temperature is equal to or warmer than nipple temperature in 93.8% of the samples.



Calculating the average and standard deviation values of Br-Nip for all five data sets shows the Standard Deviation is about the same for all sets (Table 2). The average values decline from TH1&2 and TH3 through TH4&5, however, indicating that the nipple temperature increases relative to the breast temperature as the TH evaluation increases.

**Table 2.** Breast minus Nipple (Br-Nip) temperature statistics for the five data sets.

Set	Average, °C	Std. Dev, °C
All Data	+1.1	1.1
TH1&2	+1.2	1.03
TH3	+1.0	1.0
TH4&5	+0.7	1.05
Implants	+1.0	0.93

**Legend:** "TH" indicates the Thermobiological evaluation of the infrared breast image – TH1-2 = Normal, TH3 = Equivocal, and TH4-5 = Abnormal.

Breast temperature difference ( $\Delta T_{br}$ ) and nipple temperature difference ( $\Delta T_{nip}$ ) are the other two differential measurements to be investigated. For signed difference values, this study uses Right minus Left temperature values. For unsigned values, only the magnitude of the difference is important, i.e., whether left or right is warmer is ignored.

Examining the signed average values for  $\Delta T_{br}$  and  $\Delta T_{nip}$  (Table 3), the right breast and nipple are warmer in all five data sets (the values are positive). The nipples show a greater temperature difference than the breasts in all sets. The clinical significance of these measurements may not hold for the individual case, however, due to the large standard deviations involved.

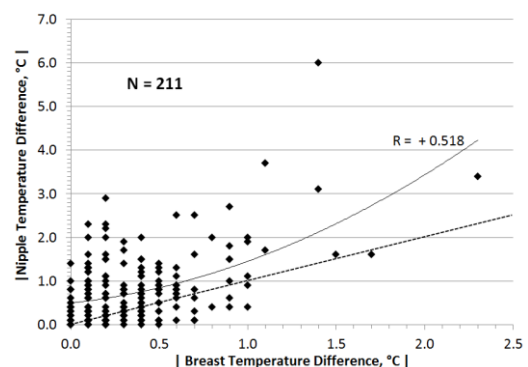
**Table 3:** Statistical analysis of signed  $\Delta T_{br}$  and  $\Delta T_{nip}$  Data. In all cases the Right breast and nipple are warmer than the Left. Average temperature values are shown. The Standard Deviation (SD) appears in square brackets: avg  $\Delta T$  [SD] °C.

Set	$\Delta T_{br}$	$\Delta T_{nip}$
All Data	+0.1 [0.47] °C	+0.5 [1.0] °C
TH1&2	+0.1 [0.3] °C	+0.3 [0.7] °C
TH3	+0.1 [0.4] °C	+0.5 [1.0] °C
TH4&5	+0.1 [0.9] °C	+0.7 [1.8] °C
Implants	+0.1 [0.29] °C	+0.4 [0.81] °C

**Legend:** "TH" indicates the Thermobiological evaluation of the infrared breast image – TH1-2 = Normal, TH3 = Equivocal, and TH4-5 = Abnormal.

As the TH evaluation increases from 1 to 5,  $\Delta T_{br}$  remains constant;  $\Delta T_{nip}$ , however, increases. The SDs of both  $\Delta T_{br}$  and  $\Delta T_{nip}$  increase from TH1 to TH5, indicating more temperature variation occurs as the TH evaluation increases. Statistics for the All Data set indicate that  $\Delta T_{nip}$  is greater than  $\Delta T_{br}$  by a factor of five around a  $\Delta T_{br}$  value of 0.1°C.

To further investigate the relationship between  $\Delta T_{br}$  and  $\Delta T_{nip}$ , the unsigned breast temperature difference ( $|\Delta T_{br}|$ ) and unsigned nipple temperature difference ( $|\Delta T_{nip}|$ ) for the All Data set is shown in Figure 6. The data trendline of Figure 6 is in agreement with the All Data set in Table 3.



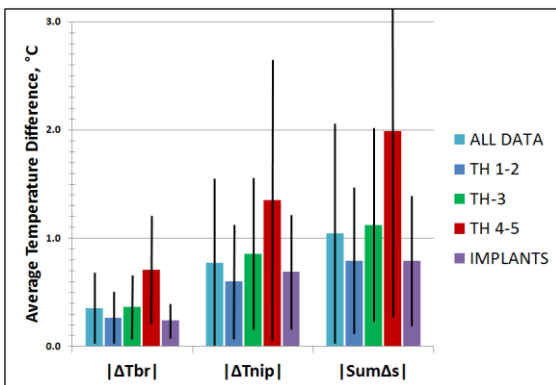
**Figure 6.** For the All Data set, a moderate correlation of  $|\Delta T_{br}|$  to  $|\Delta T_{nip}|$  is best described by a second-order polynomial trendline with  $R = +0.518$ . This graph shows that  $|\Delta T_{nip}|$  begins greater and rises faster than  $|\Delta T_{br}|$  as the differences increase. The dotted line is the equal values line.

Because both differential breast temperature and differential nipple temperature are known to increase with unilateral breast disease, the sum of the signed values of these two differentials may increase the test sensitivity. To compare this sum with  $|\Delta T_{br}|$  and  $|\Delta T_{nip}|$ , the unsigned value will be used (Equation 1).

$$|\text{Sum}\Delta s| = |(\Delta T_{br} + \Delta T_{nip})|$$

**Equation 1.**  $|\text{Sum}\Delta s|$  is the unsigned sum of the signed differential breast temperature ( $\Delta T_{br}$ ) and the signed differential nipple temperature ( $\Delta T_{nip}$ ).

The column chart (Figure 7) shows the average and standard deviation values for  $|\Delta T_{br}|$ ,  $|\Delta T_{nip}|$ , and  $|\text{Sum}\Delta s|$ . The five data sets are compared. As the TH value increases, these three categories quantitatively increase.



**Figure 7.** Average  $|\Delta T_{br}|$ ,  $|\Delta T_{nip}|$ , and  $|\text{Sum}\Delta s|$  temperature measurements are shown for the five data sets. Black lines represent +/- 1 standard deviation.

**Legend:**  $\Delta T_{br}$  = Breast temperature difference,  $\Delta T_{nip}$  = nipple temperature difference,  $\text{Sum}\Delta s$  = vector sum of  $\Delta T_{br}$  and  $\Delta T_{nip}$ .

The accepted  $\Delta T_{nip}$  cutoff value of  $1.0^{\circ}\text{C}$  can be seen in fig. 7 to cross only the TH4&5 column (Red). On observing the graph, a similar cutoff value for  $\Delta T_{br}$  would be about  $0.5^{\circ}\text{C}$ , and a cutoff value for  $\text{Sum}\Delta s$  would be about  $1.5^{\circ}\text{C}$ . The overlapping SDs (black lines), however, bring the individual clinical significance of these cutoff values into question.

## DISCUSSION

On examining the breasts with a modern thermal imager, it is apparent that, in the normal case, the nipple is distinctly different than the breast or the areola. Qualitatively, the nipple is usually cooler than the surrounding skin, showing a distinct and sharp thermal boundary separating it from the areola. (see Figure 1). This is due to the unique anatomy and physiology of the nipple compared to the remainder of the breast.

Anatomically the nipple contains very few structures. Most nipples contain 5–9 lactiferous ducts (10), several small sebaceous glands, and a circumferential ring of smooth muscle. A rugose dermis covers the nipple, obscuring the ostia of the lactiferous ducts (11).

Considering nipple vasculature, the external and internal mammary arteries provide the blood supply for the nipple. Small branches of these arteries traverse the areola and pierce the subcutaneous tissues to supply the upper and middle thirds of the nipple (12). Only small venules are present in the nipple. These become larger and drain into the areolar venous plexus and the circulus venosus of Haller which partially surrounds the areola (13). Lymphatic vessels in the nipple are quite small, draining only the local tissue spaces into the subareolar lymphatic plexus of Sappey (13).

The one structure present in the nipple that could generate excess metabolic heat is the ring of smooth muscle that contracts to prevent milk loss in the lactating breast. Striated muscle emits heat when under tension. Sustained smooth muscle contractions ‘latch’ under tension, however, emitting little heat whether relaxed or contracted (14). The finding that the nipple is usually cooler than the breast is in agreement with the lack of metabolic structures within the nipple (Figure 5 and Table 2).

As there are no significant metabolic or circulatory sources of heat in the normal human nipple, it acts as a thermal insulator. This thermal insulation is the reason the nipple dermis is normally cooler than the breast tissue beneath the nipple when the

subject is cooled for thermographic imaging.

A cool nipple is not always normal, however, especially if the nipple is painful due to local pathological vasoconstriction. The nipples, like the fingers, toes, and ears are prone to Raynaud's vasospasm (15). This syndrome causes intense nipple pain relieved by warm compresses or oral nifedipine, a vasodilating calcium channel blocker (16). Nipple fissures ("cracked nipples") are also associated with vasospasm causing the nipple(s) to be cool due to reduced local blood flow (17). Nipple fissures are a common complication of breastfeeding, which may cause nipple vasospasm (18). Nipple fissure caused by chronic abrasion ("joggers nipple") may also be associated with local vasospasm.

Although a nipple fissure is very painful and may become crusted and bleed, it does not cause local warmth unless infected secondarily (19). Instead, the affected nipple appears cool on thermography (20). Vasospasm of the small end-arterioles of the nipple along with spasm of the encircling smooth muscle of the nipple reduce blood flow to the nipple dermis, delaying or preventing healing of the fissure. Menthol, a vasodilating monoterpene volatile oil, has been shown to heal nipple fissures when applied locally (21,22).

The only major source of *increased* nipple temperature in a cooled individual is an increase in arterial blood flow to the skin or interior of the nipple. Increased local blood flow may be caused by two independent physiologic mechanisms: decreased local sympathetic tone and increased local concentration of Nitric Oxide (NO) (23,24).

That decreased sympathetic tone is associated with warm nipples is supported by thermograms of women who underwent breast reduction surgery where the areolae and nipples were transplanted without their nerve supply. These transplanted areas appear warmer than the surrounding breast skin. Even in this case, however, the nipple may be slightly cooler than the surrounding areola (25).

The effect of sympathetic tone on nipple temperature is also supported by the finding that breast and nipple temperatures are, on average, warmer on the Right (Table 3). This indicates that thoracic sympathetic adrenergic tone is, on average, stronger on the Left, causing slightly more vasoconstriction on that side. This physiologic "autonomic imbalance" is also seen in the face, where the Right side is, on average, warmer than the Left (26).

Nitric Oxide (NO) is generated locally by the enzyme Nitric Oxide Synthetase (NOS). Variants of this enzyme are found in vascular endothelium (eNOS) and other tissues and circulating cells where it is inducible (iNOS). iNOS is found in abundance in the white blood cells which respond to infection (poly-morphoneucleocytes, PMNs) (27). NO via endothelial and neural NOS may play a role in physiologic smooth muscle relaxation causing erection of the nipple. Erectile vascular sinuses are not present in the nipple (28).

Macrophages which are involved in autoimmune as well as infectious diseases contain iNOS. NO induced by reactive cytokines and microbial products gives macrophages cytostatic and cytotoxic activity against viruses, bacteria, fungi, protozoa, helminths, and tumor cells (29).

Local dermal infections of the nipple (usually staphylococcal or fungal) attract PMNs and other leukocytes which generate NO. In early infections this NO dilates local arterioles in the nipple, which may produce a warm nipple on thermography. Extension of infection into the breast tissue can occur with abscess formation, increased NO generation, and enlargement of the hyperthermic area over the areolar and breast areas (30).

Nipple warmth may indicate early tumor growth within a lactiferous duct. Besides NO being generated by macrophages as they attack a tumor, the early intraductal tumor itself may generate NO. NOS is expressed early in breast carcinoma, with a high rate of NOS expression within in situ carcinomas such as Ductal Carcinoma In Situ (DCIS) (31). The diffusible, gaseous

NO generated within a lactiferous duct, either by tumor cells or leukocytes, will be directed along the duct to the nipple dermis where it diffuses into the local tissues and dilates the dermal arterioles, warming the nipple in relation to the surrounding breast. NOS is detected predominantly in noninvasive and invasive breast lesions but rarely in benign lesions (31). A nipple temperature increase may be an important early sign of DCIS and other pathologies.

Observing the differential data as TH1&2 rises through TH4&5, the Br-Nip value decreases (i.e., nipple temperature increases) and the nipple temperature difference ( $\Delta T_{nip}$ ) rises. A negative Br-Nip value (nipple warmer than the ipsilateral breast) along with a high  $\Delta T_{nip}$  value should arouse suspicion of underlying breast disease. Addition of this finding to Ville-Marie TH Infrared Grading Scale as a significant abnormality should be considered.

The presently accepted  $\Delta T_{nip}$  cutoff value of  $1.0^{\circ}\text{C}$  is confirmed graphically by these data (Figure 7). In the absence of nipple pain,  $\Delta T_{nip}$  values above  $1.0^{\circ}\text{C}$  indicate possible breast disease in the breast with the warmer nipple. This study is in agreement with the addition of this cutoff as an abnormal finding to the Ville-Marie TH Infrared Grading Scale (32).

Also from the graph of Figure 7, a breast temperature difference ( $\Delta T_{br}$ ) greater than  $0.5^{\circ}\text{C}$  should arouse suspicion, especially if  $\Delta T_{nip}$  is above  $1.0^{\circ}\text{C}$  and the warmer breast and warmer nipple are ipsilateral. This can be determined mathematically as the Sum $\Delta$ s value (see Equation 1). A Sum $\Delta$ s value greater than  $1.5^{\circ}\text{C}$  should arouse concern.

The results and conclusions of this study are limited in that the data was collected at a single clinic in a temperate climate. Also, TH evaluations were performed by a single thermographer. The subjects were predominantly Caucasian middle-class women. Confirmation of these results at other thermographic centers located in diverse climates and using multiple interpreting thermographers is necessary. Also, the study should be repeated with more races

– Black, Hispanic, oriental, Caucasian, and indigenous – as subjects. Pooled data from thermography centers around the world are needed to confirm the results of this study. To confirm any correlation of nipple temperature and DCIS, a study comparing breast thermography to microscopic biopsy results will be necessary.

## CONCLUSIONS

Absolute breast temperatures are strongly correlated with ipsilateral nipple temperatures ( $R = +0.763$ ). Absolute nipple temperatures are almost always cooler than the ipsilateral breast temperature. Absolute average breast temperatures decrease by about  $1^{\circ}\text{C}$  from age 27 to 80, but this correlation is weak ( $R = -0.167$ ). Nipple temperature does not significantly vary with age ( $R = -0.040$ ).

Differential measurements avoid the variance in absolute temperature measurements. Breast temperature minus ipsilateral nipple temperature (Br-Nip) averaged  $+1.1^{\circ}\text{C}$  with a two-tailed Gaussian Standard Deviation of  $1.1^{\circ}\text{C}$ . This again shows nipple temperatures are almost always cooler than the breast. Nipple temperature difference tends to change faster than breast temperature difference (see Figure 6).

In the All Data set, the Right breast averaged  $0.1^{\circ}\text{C}$  warmer than the Left and the Right nipple averaged  $0.5^{\circ}\text{C}$  warmer than the Left. The greater temperature on the Right was seen in all data sets. The laterality of this thoracic “autonomic imbalance” is in agreement with thermal data from the face, which also shows the Right side to be warmer, on average.

The Sum $\Delta$ s value (see Equation 1) greater than  $1.5^{\circ}\text{C}$  should arouse concern. Isolated nipple warmth, whether greater than the ipsilateral breast temperature or significantly greater than the contralateral nipple temperature, may indicate the presence of early nipple infection or intraductal malignancy. More study on the correlation of nipple temperatures with DCIS is warranted.



## ACKNOWLEDGMENTS

Thanks to Ms. Joyce Cary, President of Integrative Life Solutions, Inc. (ILSI), and to all the staff at ILSI who facilitated seven years of thermography service. Thanks also to my co-author, M. Nathaniel Mead, MSc, for his interest in the thermography of DCIS; and to William Williams, DSc, who helped prepare the large Excel spreadsheet on which this study is based.

## DISCLOSURES

The author (JSC) is one author of the book *Human Medical Thermography*, CRC Press, Boca Raton, FL USA, 2022. DOI: 10.1201/9781003281764. Dr. Campbell receives a royalty for book sales. The book is referenced several times in this paper.

## REFERENCES

- Diakides NA and Bronzino JD, eds., *Medical Infrared Imaging*. CRC Press, 2008, ISBN: 978-0-8493-9027-2, page 2-3
- GWA Dummer & J Mackenzie Robertson, eds. *Medical Electronic Laboratory Equipment 1967-68*. Pergamon Press. 1967, p.530.
- Adams, F.: *The Genuine Works of Hippocrates*. Baltimore: Williams and Wilkins, 1939.
- Lawson RN. Thermography—a new tool in the investigation of breast lesions. *Can Serv Med J* 1957; 13:517
- The American Academy of Thermology, available online. <https://aathermology.org/wp-content/uploads/2018/04/AAT-Breast-Guidelines-2021v2.pdf> Accessed 10 Feb 2023
- Diakides NA and Bronzino JD, eds., *Medical Infrared Imaging*, Table 10.1
- Fluke Corporation. Available online. <https://www.fluke.com/en-us/product/thermalcameras/tix500#specs-tab> Accessed 5 Feb 2023
- Campbell JS & Mead MN, *Human Medical Thermography*, CRC Press, Boca Raton, FL, 2022, DOI: 10.1201/9781003281764.
- de Souza G, et.al, Reference breast temperature: proposal of an equation. *einstein*. 2015;13(4):518-24, DOI: 10.1590/S1679-45082015AO3392
- Love SM and Barsky SH. *Anatomy of the Nipple and Breast Ducts Revisited*. *Cancer* 2004;101:1947–57, DOI 10.1002/cncr.20559
- Quizlet, Inc. Available online. <https://quizlet.com/279519146/breast-nipple-anatomy-diagram/> Accessed 12 Jan 2023
- Nakajima H, et.al, Arterial anatomy of the nipple-areola complex, *Plast Reconstr Surg*. 1995 Sep;96(4):843-5. PMID: 7652057
- Gray H, *Anatomy of the Human Body*, 27th ed, Lea & Febiger, Philadelphia, 1965, p.1385, ASIN: B004852EZW
- Murphy RA and Rembold CM, The Latch-bridge Hypothesis of Smooth Muscle Contraction. *Can J Physiol Pharmacol*. 2005 October; 83(10): 857–864. doi: 10.1139/y05-090
- Wu M, et.al, Raynaud's phenomenon of the nipple, *Obstet Gynecol*. 2012 Feb;119:447-449, PMID: 22270434, DOI:10.1097/AOG.0b013e31822c9a73
- Anderson P, *Drug Treatment of Raynaud's Phenomenon of the Nipple*. *Breastfeeding Medicine* Vol 15, No 11, 2020 DOI: 10.1089/bfm.2020.0198
- Buck M, et.al, Nipple Pain, Damage, and Vasospasm in the First 8 Weeks Postpartum. *Breastfeeding Medicine* Vol 9, No 2, 2014, DOI: 10.1089/bfm.2013.0106
- Douglas P, Re-thinking lactation-related nipple pain and damage. *Women's Health*, Vol 18: 1–29, 2022, DOI: 10.1177/17455057221087865
- Potter H, The sensitivity of thermography to temperature changes in breast tissue. *Australian J Physiotherapy* Vol

- 43, No 3, 1997, Pages 205-210. DOI: 10.1016/S0004-9514(14)60411-6.
20. di Migueli M, et.al, Thermography study of nipple-areola complex in immediate Puerperas. *Manual Therapy, Posturology & Rehabilitation Journal* 2016, doi: 10.17784/mtprehabjournal.2016.14.389
  21. Craighead D & Alexander L, Menthol-Induced Cutaneous Vasodilation Is Preserved in Essential Hypertensive Men and Women. *Am J Hypertension* 30(12) December 2017, doi:10.1093/ajh/hpx127.
  22. Amir Ali Akbari S, et.al, Effects of menthol essence and breast milk on the improvement of nipple fissures in breastfeeding women. *J Res Med Sci* 2014; 19:629-33. PMID: 25364362 PMID: PMC4214021
  23. Diakides NA and Bronzino JD, eds., *Medical Infrared Imaging*, pp 6-3 and 6-4.
  24. Anbar, M, *Quantitative Dynamic Telethermometry*, CRC Press, Boca Raton, FL, USA, 1994. ISBN: 0-8493-4409-3, pp 23-27.
  25. Campbell & Mead, *Human Medical Thermography*, Figure 9.26.
  26. Campbell, JS, et.al, Fact or Fiction? Exploring Two Beliefs about Oral-Systemic Thermology. Presented at the American Academy of Thermology (AAT) Annual Meeting, Atlanta, GA, September 2019
  27. Sethi S & Dikshit M, Modulation of Polymorphonuclear Leukocytes Function by Nitric Oxide. *MINI-REVIEW| Vol 100, Issue 3, Nov 2000, P223-247, DOI:10.1016/S0049-3848(00)00320-0*
  28. Tezer M, Nitric Oxide May Mediate Nipple Erection, *J Androl* 2012;33:805–810, DOI: 10.2164/jandrol.111.014951
  29. MacMicking J, et.al, Nitric oxide and macrophage function. *Annu Rev Immunol.* 1997;15:323-50. PMID: 9143691.
  30. AbdelHadi M & Bukharie H, Breast Infections in Non-Lactating Women. *J Family Community Med.* 2005 Sep-Dec; 12(3): 133–137. PMID: 23012091
  31. Loibl S, et.al, Expression of Endothelial and Inducible Nitric Oxide Synthase in Benign and Malignant Lesions of the Breast and Measurement of Nitric Oxide Using Electron Paramagnetic Resonance Spectroscopy. *Cancer* 2002;95:1191–8. DOI 10.1002/cncr.10817.
  32. Campbell & Mead, *Human Medical Thermography*, p.101